

05/25/17

JEFFREY BODIN
528 BEAU CHENE DR
MANDEVILLE, LA 70471

JEFFREY BODIN

has an appointment with

Dana LeBlanc

on

05/24/2018 at 12:45 P

at our location

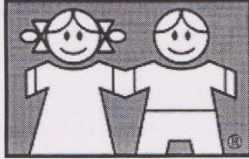
200 Henry Clay Avenue
New Orleans, LA 70118-5720
(504) 899-9511

Thank you,

The Physicians and Staff at
Children's Hospital Multispecialty Clinic

You need to see if
Medicaid pays for
this visit
w/this Dr.
OK?

Bodin, Jeffrey (MR # 1002548110)



CHILDREN'S HOSPITAL

Ms. Cherie
↓ Dr. Leonard's
Nurse

Facility

Name Children's Hospital Hematology and Oncology	Address 200 Henry Clay Ave. New Orleans LA 70118-5720	Phone 504-896-9740	Fax 504-896-9758
---	---	-----------------------	---------------------

Jeffrey Bodin
AVS

MRN: **1002548110**
Description: **21 year old male**

Why you were hospitalized

Your primary diagnosis was: Not on File

Allergies as of 5/24/2018

Allergies	Reactions
Latex	Rash

Medication List

ASK your doctor about these medications

	Morning	Noon	Evening	Bedtime	As Needed
ALEVE 220 MG tablet Take 1,000 mg by mouth 2 (two) times daily with meals Generic drug: naproxen sodium					
buPROPion 300 MG 24 hr tablet Take 300 mg by mouth daily Commonly known as: WELLBUTRIN XL					
dextroamphetamine-amphetamine 20 mg Tab per tablet Take 20 mg by mouth 3 (three) times daily Commonly known as: ADDERALL					
DYMISTA 137-50 mcg/spray Spry 1 spray by Nasal route daily Generic drug: azelastine-fluticasone					
montelukast 10 mg tablet Take 10 mg by mouth daily Commonly known as: SINGULAIR					

Patient Instructions

Instructed on Return and Follow up Plan including any test times, NPO status and special instructions.
Expressed understanding of: Medication(s) prescribed/administered, need to contact us for fever greater than 100.4 degrees, nausea, vomiting, diarrhea or any other change in status, complications or concerns.
Instructed to carry a copy of all current medications to all appointments.

Appointment with Dr. Gonzales tomorrow, 5/25 at 12:45pm (ortho).

Bodin, Jeffrey (MR # 1002548110)

Patient Instructions (continued)

Other Orders Instructions

Ambulatory Referral to Dermatology

Last derm evaluation was July 2017

Complete by: Jun 06, 2018

Clinic Appointment Request

Complete by: May 23, 2019

Future Appointments

05/25/2018 12:45 PM CDT

(Arrive by 12:15 PM)

Orthopedics New Patient with Joseph Gonzales, MD
Children's Hospital Orthopedics (CHNO ACC 1st Fl)

200 Henry Clay Ave.
New Orleans LA 70118-5720
504-896-2888

05/23/2019 1:30 PM CDT

(Arrive by 1:15 PM)

Hem Onc Established Patient with Dana Marie Leblanc,
MD
Children's Hospital Hematology and Oncology (CHNO
ACC 1st Fl HemOnc)

200 Henry Clay Ave.
New Orleans LA 70118-5720
504-896-9740

MyChart Sign Up Instructions

Welcome to myLCMC Health, a secure online medical record exclusively for patients of the hospitals within the LCMC Health family. myLCMC Health allows you to send messages to your physician and health care providers, renew your prescriptions, view your test results, and more.

myLCMC Health should **NOT** be used for urgent needs. For medical emergencies, dial **911**.

To sign up, visit <https://www.MyLCMCHealth.org>. Click "Sign Up Now" and enter your access code exactly as it appears below:

DK7FN-CQ86Q-HDVPT

Expires: 7/23/2018 3:58 PM

If you have questions about MyLCMCHealth, ask your doctor or nurse today. After activating your account, view the Quick Start Guide under the Resource tab to learn more about the features available to you. For technical assistance, call our toll free number 866-662-6161 or email your question(s) to MyChart@LCMCHealth.org

Patient Signature: _____
Date: _____

Bodin, Jeffrey Printed at 5/24/18 4:41 PM

Bodin, Jeffrey Printed at 5/24/18 4:41 PM

XR Chest Ap Pa Lateral 2 VW

Status: **Final result**

PACS Images

Show images for XR Chest Ap Pa Lateral 2 VW

Study Result

CHEST AP AND LATERAL:

The lungs are symmetrically overinflated otherwise clear. Heart size and pulmonary vascularity are within normal limits. Aortic arch is left-sided. Pectus deformity of the chest is more pronounced since 1/5/2015. There is a presternal radiopaque screw projecting along/within the anterior chest wall. The right humeral head appears fractured and anteriorly dislocated. There are mild to moderate anterior wedge compression deformities of 2 midthoracic vertebral bodies which were not evident on prior exam dated 1/5/2015, and there is increased kyphoscoliosis.

IMPRESSION:

Underinflated otherwise clear lungs. Increased pectus deformity with a presternal radiopaque screw projecting along/within the anterior chest wall. Anterior fracture-dislocation of the right humeral head and anterior wedge compression deformities of two mid thoracic vertebral bodies with increased kyphoscoliosis, suspect pathologic fractures. Correlation with right shoulder radiographs and whole body nuclear medicine bone and/or PET/CT scan may be helpful for further characterization if clinically warranted.

Electronically Signed By: David Manning, M.D. 5/24/2018 2:28 PM CDT

Imaging

XR Chest Ap Pa Lateral 2 VW (Order #98042848) on 5/24/2018 - Imaging Information

Result History

XR Chest Ap Pa Lateral 2 VW (Order #98042848) on 5/24/2018 - Order Result History Report

In Basket Actions

Reviewed Result Note View in In Basket

Signed by

Signed	Date/Time	Phone	Pager
MANNING, DAVID A	5/24/2018 14:28	504-896-9565	

Interpreted by

Interpreting	Date/Time
David A Manning, MD	5/24/2018

Exam Information

Status	Exam Begun	Exam Ended
Final [99]	5/24/2018 13:42	5/24/2018 13:53

PACS Images

Show images for XR Chest Ap Pa Lateral 2 VW

External Result Report

External Result Report *

Encounter

View Encounter

Order Report

XR Chest Ap Pa Lateral 2 VW (Order #98042848) on 5/24/18

Reprint Order Requisition

XR Chest Ap Pa Lateral 2 VW (Order #98042848) on 5/24/18

PACS Images

Show images for XR Chest Ap Pa Lateral 2 VW

Order Questions

Question	Answer	Comment
Exam reason Note: Enter reason for exam	hx of melanoma	

Bodin, Jeffrey [1002548110] - DOB: 5/22/1997 - Review Flowsheets

Component	Latest Ref Rng & Units	5/24/2018
WBC	3.70 - 11.70 10 ³ /uL	6.08
RBC	4.50 - 5.90 10 ⁶ /uL	5.20
HEMOGLOBIN	13.5 - 17.5 gm/dL	15.6
Hematocrit	35.0 - 46.0 %	46.9 (H)
MCV	75.0 - 97.0 fL	90.2
MCH	24.0 - 32.0 pg	30.0
MCHC	31.0 - 35.0 g/dL	33.3
RDW	11.5 - 15.4 %	11.9
RDW-SD RESULT	35.1 - 46.3 fL	39.3
Platelet Count	135 - 450 10 ³ /uL	318
MPV	8.6 - 12.4 fL	9.3
nRBC	0 10 ³ /uL	0.00
nRBCs	0 /100 WBC	0
ABS NEUTROPHIL, AUTO RESULT	1.8 - 7.7 10 ³ /uL	3.4
ABS LYMPHOCYTE, AUTO RESULT	1.2 - 5.2 10 ³ /uL	2.1
ABS MONOCYTE, AUTO RESULT	0.2 - 0.4 10 ³ /uL	0.5 (H)
ABSOLUTE EOSINOPHILS	0.0 - 0.3 10 ³ /uL	0.0
ABSOLUTE BASOPHILS	0.0 - 0.0 10 ³ /uL	0.1 (H)
NEUTROPHILS RESULT	%	55.4
Lymphocytes	%	34.0
Monocytes	%	8.6
Eosinophils	%	0.5
Basophils	%	1.2
SODIUM	134 - 144 mmol/L	142
POTASSIUM	3.4 - 5.5 mmol/L	3.7
CHLORIDE	98 - 107 mmol/L	104
CO2	20 - 31 mmol/L	29
GLUCOSE	65 - 110 mg/dL	68
BUN	7.0 - 21.0 mg/dL	15.0
Creatinine	0.20 - 1.40 mg/dL	0.80
CALCIUM	8.5 - 10.4 mg/dL	9.8
Total Protein	6.5 - 8.0 g/dL	6.9
Albumin	3.0 - 4.8 g/dL	4.5
AST	8 - 53 U/L	19
ALT	7 - 56 U/L	26
ALKALINE PHOSPHATASE CD MODIFIER RESULT	39 - 253 U/L	113
Bilirubin, Total	0.3 - 1.3 mg/dL	0.3
eGFR,AFRICAN AMERICA RESULT	>89 mL/min	>105
eGFR,NON-AFR AMERICA RESULT	>89 mL/min	>105