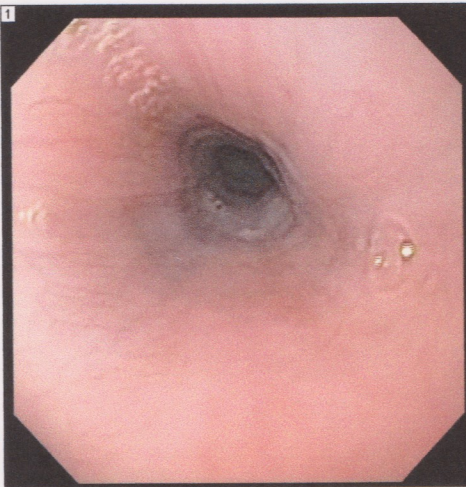


Children's Hospital of New Orleans

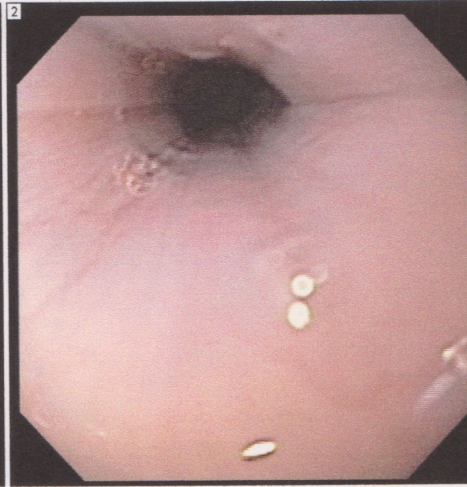
Esophagogastroduodenoscopy Exam Images

Patient: Jeffrey Bodin
Patient ID: MRN-0445573
Exam Date: 10/15/2009

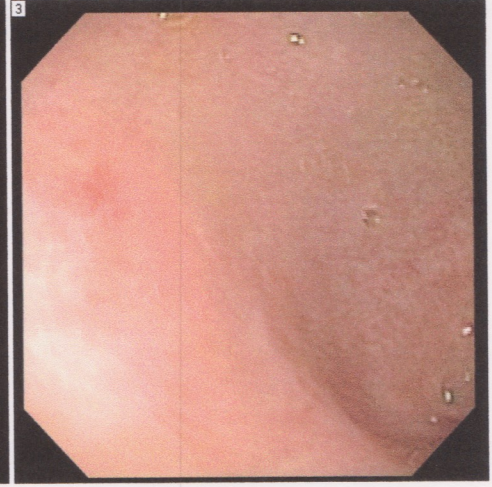Attending Physician: Raynorda Brown M.D.
Referring Physician:



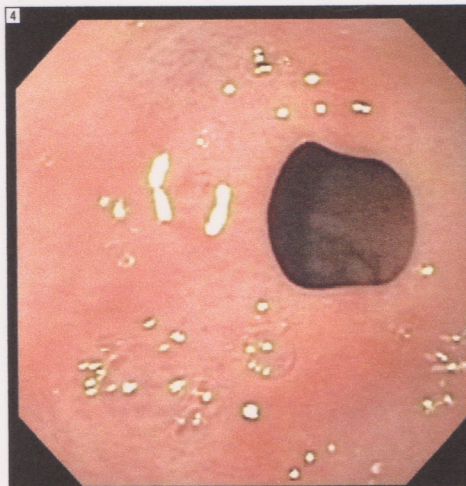
1 normal-esophagus-middle third of the esophagus



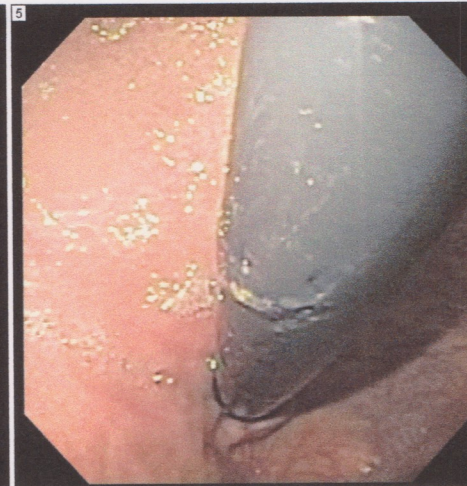2 normal-esophagus-distal third of the esophagus



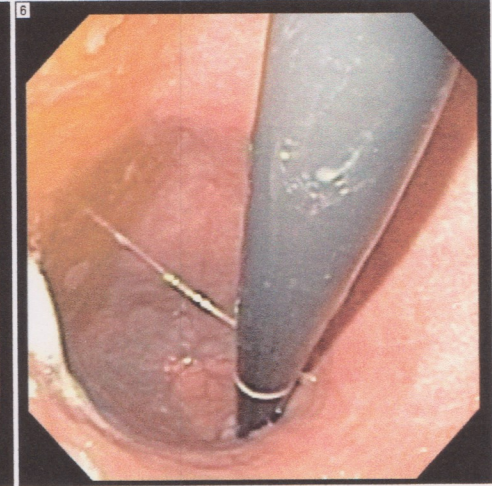
3 erosion-stomach-anterior wall of the antrum



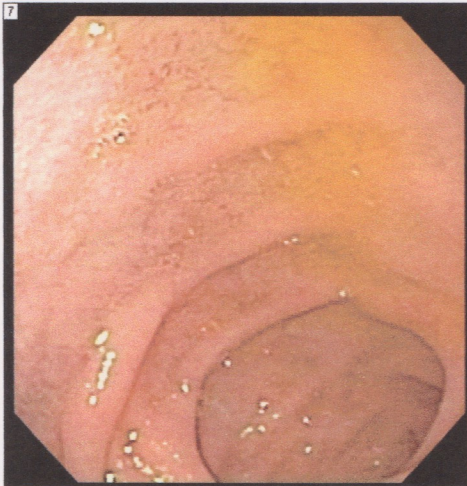erythematous mucosa-pylorus



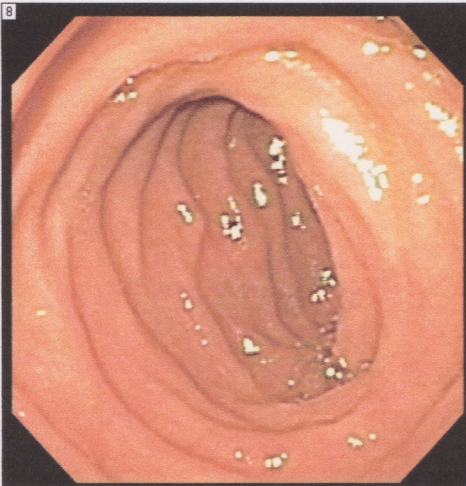
5 normal-stomach-cardia



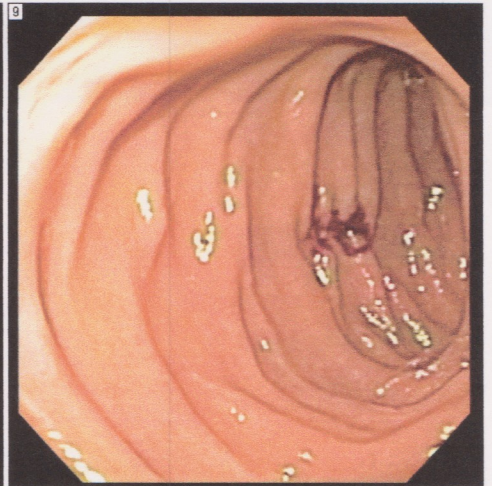
6 erythematous mucosa-stomach-fundus



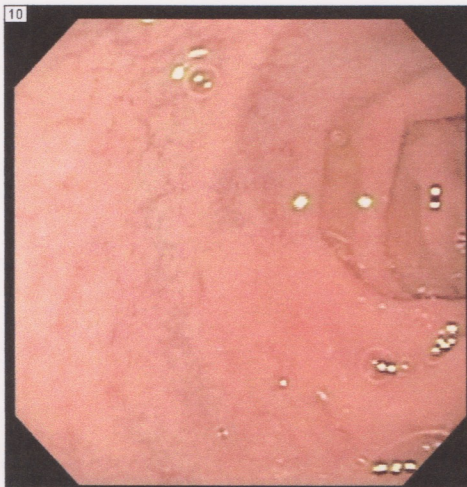7 normal-duodenum-2nd portion of the duodenum



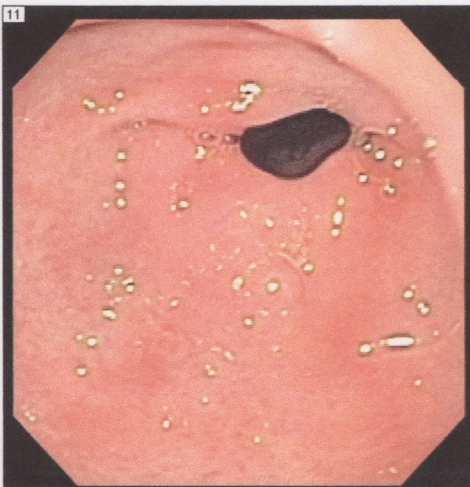
8 normal-duodenum-3rd portion of the duodenum



9 post biopsy, duodenum



10-distal bulb



11 erythematous mucosa-pylorus

