

Proliferating Cell Nuclear Antigen as a Molecular Biomarker for Spermatogenesis in PTU-Induced Hypothyroidism of Rats

Reproductive Sciences
18(7) 679-686
© The Author(s) 2011
Reprints and permission:
sagepub.com/journalsPermissions.nav
DOI: 10.1177/1933719110395401
http://rs.sagepub.com


Ehab Tousson, PhD¹, Ehab M. M. Ali, PhD²,
Wafaa Ibrahim, MD³, and Mohammed A. Mansour, BSc²

Abstract

The thyroid hormone has few serious effects on the testes except during the neonatal stage. There is little knowledge concerning the prolonged effect of thyroid hormone deficiency throughout the rat's life span and its effect on spermatogenesis. Proliferating cell nuclear antigen (PCNA) is a nuclear matrix protein, which is essential for multiple cell cycle pathways. Here we used PCNA immunohistochemistry as a marker to differentiate between the testes of control and hypothyroid rats. About 20 rats were equally divided into 2 groups; the first group was the control group, while the second group was the experimental group in which rats were fed 0.05% 6-n-propyl thiouracil (PTU) in drinking water for 6 weeks. Immunohistochemistry, using an antibody against PCNA, showed at least 3 differences in the pattern of PCNA immunoreactivity (PCNA-ir). First, PCNA-ir was not detected in Sertoli and Leydig cells in the testes of control rats and detected in some of the hypothyroid rats. Second, in the control group more than 96% of spermatogonia were PCNA-positive cells; however, hypothyroidism caused the reduction to approximately 25% PCNA staining in spermatogonia. The third difference was in the abnormal distribution of spermatogonia seen in the hypothyroid rat testis, not in the control one. These results suggest that prepubertal hypothyroidism affects the proliferation of spermatogenic cells leading to impaired spermatogenesis and that PCNA index is a useful marker for assessing germ cell kinetics and spermatogenesis in prepubertal hypothyroidism.

Keywords

Testes, hypothyroidism, PTU, spermatogenesis, PCNA, rats

Introduction

Appropriate level of thyroid hormone is essential for normal development and metabolism in most vertebrate tissues, and altered thyroid status adversely affects them.^{1,2} For many years, the testis was regarded a thyroid hormone unresponsive organ, but consistent evidence accumulated in the past 2 decades has definitively changed this classical view.

The testes are mainly regulated by the gonadotrophin follicle-stimulating hormone (FSH) and luteinizing hormone (LH), the latter acting through the intermediate testosterone secreted by the Leydig cells.^{3,4} It is well accepted that these systemic hormones and local testicular paracrine-autocrine factors work together to initiate and maintain testicular function and sperm production.⁵ Apart from gonadotrophins, thyroid hormone has also been shown to play an important role in testicular physiology.^{2,6,7} It is now established that triiodothyronine (T3) regulates the maturation and growth of testis, in rats and other mammal species, by inhibiting immature Sertoli cell proliferation and stimulating their functional differentiation.⁸⁻¹⁰ Similarly, thyroid hormone has also been shown to play a critical role in the onset of Leydig cell differentiation and stimulation of steroidogenesis in postnatal rat testis.^{11,12}

Although the basic mechanisms involved in the regulatory actions of thyroid hormone in testicular cells are still undefined, the presence of thyroid hormone receptors (TRs) in human and rat testes throughout development and in adulthood implies that T3 may act directly via the classical genomic pathway in this organ.^{2,8,13}

Altered thyroid status, experimentally induced or occurring in adult life, is frequently associated with some kind of sexual dysfunction and/or morphological testicular degeneration.¹⁴⁻¹⁷ Because most experimental studies to date have focused on thyroid hormone effects on the developing testes, only limited data are available on its role in spermatogenesis.

¹ Department of Zoology, Tanta University, Egypt

² Biochemistry Section, Department of Chemistry, Faculty of Science, Tanta University, Egypt

³ Department of Medical Biochemistry, Faculty of Medicine, Tanta University, Egypt

Corresponding Author:

Ehab Tousson, Department of Zoology, Tanta University, Egypt
Email: toussonehab@yahoo.com

Proliferating cell nuclear antigen (PCNA) is a well-known 36-kDa nuclear matrix protein, which is essential for multiple cell cycle pathways, including DNA replication, DNA elongation (leading strand synthesis), and DNA excision repair.^{18,19} It is also utilized in cell cycle control through direct interaction with cyclin/cdk complexes, allowing progression through the G1/S boundary of the cell cycle.²⁰ Proliferating cell nuclear antigen is an essential component of the DNA replication machinery, acting as the processing factor for polymerases.²¹ In addition to its role in replication, PCNA is also required for nucleotide excision repair and plays a role in 1 pathway of base excision repair.²² Analysis of proteins that interact with PCNA has shown that it not only interacts with enzymes involved in the mechanics of DNA repair and replication but also binds to cell cycle regulatory proteins such as p21 and Gadd45.^{23,24} Proliferating cell nuclear antigen is useful for the diagnosis of germinal arrest because there are significantly reduced PCNA levels in germinal arrest, which is an indication of DNA synthesis deterioration.²⁵ In this study, a detailed histopathological examination was performed, including PCNA immunohistochemistry of rat testicular tissue to analyze the proliferation rate of the germ cells and to examine the effects of 6-n-propyl thiouracil (PTU)-induced hypothyroidism on the proliferative aspects of spermatogenesis.

Materials and Methods

The experiments were performed on 20 male albino rats (*Rattus norvegicus*) weighing 120 g (± 10 g) and of 6 to 7 weeks' age. They were obtained from Helwan laboratory farms of the Egyptian Organization for Vaccine and Biologic Preparations. The rats were kept in the laboratory for 1 week before the experimental work and maintained on a standard diet and water available ad libitum. The temperature in the animal room was maintained at $23 \pm 2^\circ\text{C}$ with a relative humidity of $55\% \pm 5\%$. Light was on a 12:12-hour light–dark cycle. The experimental protocol was approved by local ethics committee and animals research. The rats were equally divided into 2 groups: the first group was the control group in which rats never received any treatment; while the second group was the experimental group in which rats received 0.05% PTU in drinking water for 6 weeks.²⁶

At the end of the experimental period, 5 rats from each group were euthanized with intravenous injection with sodium pentobarbital and subjected to a complete necropsy. Blood samples were individually collected from each rat in nonheparinized glass tubes. Serum was separated by centrifugation at 3000 rpm for 15 minutes. The collected serum was stored at -18°C until analysis. Serum was analyzed to determine the T3 and thyroid-stimulating hormone (TSH) levels.

Determination of Serum T3 and TSH Concentrations

Serum T3 was assayed using commercial test supplied by the Diagnostic systems Laboratories (DSL), Texas. Serum TSH

was assayed using commercial kit supplied by Coat-A-Count TSH IRMA, Los Angeles, California.

Proliferating Cell Nuclear Antigen Immunohistochemistry

The other 5 rats from each group were anesthetized with thiopental. Through surgical incision on the sternum, the thorax was opened and the perfusion was done from left ventricle and right atrium. A rinsing solution was perfused before the fixation solution (Bouin fluid). Due to the narrow testicular artery branches from the abdominal aorta near the renal artery, it is probably constricted and occluded during the perfusion process. Perfusion with rinsing solution helped overcome this problem. To make rinsing solution, 9.0 g NaCl, 25 g polyvinylpyrrolidone, 0.25 g heparin, and 5.0g procaine-HCL were dissolved in 1 L of water by thorough stirring. The pH was adjusted to 7.35 with 1 N NaOH and twice filtered through Millipore filters of 3.0 μm or less pore size. The perfusion of both solutions was performed using a scalp vein attached to a 50 cc syringe. Testes were immediately removed, taking care to handle specimens gently to minimize trauma to the delicate seminiferous tubules prior to the placement of each testis into fixative solution. The tunica albuginea was shallowly pierced at each pole 5 times with a 21-gauge needle to aid in the penetration of the fixative solution. Fixation time was limited to 24 hours and tissues were transferred to 70% ethyl alcohol. Alcohol was changed 3 times daily for 2 days before transferring the specimens to a saturated solution of 70% ethyl alcohol and lithium carbonate to neutralize the picric acid in Bouin fluid. The ethyl alcohol-lithium carbonate solution was changed 3 or more times until the yellow color of Bouin fluid was almost completely depleted from the tissue. Testes were stored in 70% ethyl alcohol until they were processed.²⁷ The fixed testes were dehydrated through a graded series of ethanol and embedded in paraffin, according to standard procedures. Paraffin sections (5 μm thick) were mounted on gelatin chromalum-coated glass slides and stored at room temperature until further processing. The 5 μm thick paraffin sections were used for PCNA immunohistochemical staining method.²⁸

Testicular distribution of PCNA receptor subunits were examined in deparaffinized sections (5 μm) of Bouin fixed testes of rats using an avidin–biotin–peroxidase (ABC) immunohistochemical method (Elite-ABC, Vector Laboratories, California) against PCNA (dilution 1:100, DAKO Japan Co, Ltd, Tokyo, Japan). Briefly, sections were deparaffinized, rehydrated, washed in phosphate buffered saline ([PBS] 3×5 minutes) and peroxidase activity was quenched using 0.3% H_2O_2 in methanol for 30 minutes. Subsequently, samples were washed in PBS and incubated with blocking solution at room temperature for 10 minutes. After rinsing with PBS, sections were incubated with biotinylated mouse PCNA primary antibody in moist chamber for 30 to 60 minutes and then rinsed with PBS. Samples were incubated with streptavidin peroxidase at room temperature for 10 minutes and washed with PBS. The antibody–peroxidase complex was developed using the

diaminobenzidine (DAB) chromogen at 18–24°C for 2–5min. Finally, the sections were washed with PBS, counterstained with hematoxylin for 1 minute, washed with tap water then PBS for 30 seconds, dehydrated through ascending grades of alcohol, delipidated in xylene, and coverslipped with Mount-Quick (Daido Sangyo, Tokyo). All stained slides were viewed using Olympus microscope and images were captured by a digital camera (Canon PowerShot A620). Brightness, contrast, and analysis of the images were adjusted using Adobe Photoshop software (version 4.0.1; Adobe Systems, Mountain View, California).

PCNA-Labeling Index

We determined the PCNA labeling index (PCNA-LI) in the PCNA immunoreactive slides by slide examination under the light microscope with a magnification of $\times 200$ and with the help of PAX-it image analysis software. Selected sections were evaluated for PCNA immunostaining. Microscopic fields were chosen at random and 5 fields per slide were evaluated. Only the basal germ cells of the seminiferous tubules were counted, as they are the cells where active DNA synthesis took place.²⁹ The PCNA-LI for each seminiferous tubule was estimated as a percentage of immunolabeled cells (cells with brown nuclear staining PCNA+) to all basal cells.³⁰ The average PCNA index in each case was obtained by dividing the sum of all PCNA indices by the number of seminiferous tubules in which the calculation was carried out. For each specimen the mean \pm SD was calculated.

Statistical Analysis. Data were expressed as mean values \pm SD and statistical analysis was performed using 1-way analysis of variance (ANOVA) to assess significant differences among treatment groups. The criterion for statistical significance was set at $P < .05$. All statistical analyses were performed using SPSS statistical version 16 software package (SPSS Inc., IBM Company; Somers, NY 10589 USA).

Results

Serum T3 levels were significantly lower in hypothyroid rats compared with the control. On the other hand, serum TSH levels in rats were significantly higher than those found in the control rats (Table 1).

The light microscopy examination of the testis of the control rats showed a normal structure completely enveloped by a thick capsule, tunica albuginea, which is composed mainly of dense collagenous fibrous connective tissue. The structural components of the testis are the seminiferous tubules and interstitial tissues (Figure 1A). The interstitial cells (Leydig cells) of control rats are found in the connective tissue between the seminiferous tubules and showed a negative reaction for PCNA-ir (Figure 1B). The seminiferous tubules are of 2 types of cells, the Sertoli cells, resting on the thin basal lamina (basement membrane) and the spermatogenic cells. Figure 1F shows a negative reaction for PCNA-ir in Sertoli cells of control rats,

Table 1. Serum T3 and TSH Levels and PCNA Index in Testes Tissues of Control and Hypothyroid Rats

Groups	Parameters		
	Total T3 (ng/dL)	TSH (mIU/mL)	PCNA-LI
G ₁ (control), mean \pm SD	155.8 \pm 30.335	0.014 \pm 0.006 $\times 10^{-3}$	96.33 \pm 5.59
G ₂ (PTU-induced hypothyroidism), Mean \pm SD	56 \pm 11.023 ^a	4.1 \pm 0.7 $\times 10^{-3}$ *	19.45 \pm 3.55

Abbreviations: T3, tri-iodothyronine; TSH, thyroid-stimulating hormone; PCNA, proliferating cell nuclear antigen; LI, labeling index; PTU, 6-n-propyl thiouracil; SD, standard deviation.

^a $P < .001$ vs control rats.

which can be identified by their oval- or pear-shaped vesicular nuclei lying perpendicular on the basement membrane of seminiferous tubules (data not shown). The spermatogenic cells are arranged in many layers, namely, the spermatogonia; primary and secondary spermatocytes; spermatoids; and finally mature spermatozoa. Only the spermatogonia in control animals showed a positive strong reaction for PCNA-ir (Figure 1), while the other spermatogenic cell types showed negative reaction (Figure 1C and D). The lumen of the seminiferous tubules in the control group was fully packed with sperms that showed a negative reaction for PCNA-ir (Figure 1A-C).

The testes of hypothyroid rats showed many immunohistochemical changes in testicular tissues (Figure 2). Table 1 presents the index PCNA value and the number of PCNA-ir-positive germ cells per tubule cross-section significantly decreased following PTU treatment (19.45 \pm 3.55) in comparison to the control group (96.33 \pm 5.59). The number of spermatozoa is less in hypothyroid rats, where the lumen of some seminiferous tubules was clear and the spermatozoa were not seen (Figure 2A and B). Some of the Sertoli cells in the seminiferous tubules of hypothyroid rats showed positive reaction for PCNA in contrast to the control group (Figure 2C). Figure 2D shows positive reaction for PCNA in some Leydig interstitial cells lying between seminiferous tubules of hypothyroid rats in contrast to the control group. The distribution of spermatogonia in seminiferous tubules of hypothyroid rats is not homogenous as in control animals (Figure 2E and F). Some of the spermatogonia in the testes of hypothyroid rats were observed in the lumen of the seminiferous tubules and between the spermatocytes (Figure 2E and F).

Discussion

The thyroid hormone is essential for the development and maintenance of the testes. In previous studies, the thyroid hormone has few serious effects on the testes except during the neonatal stage when the thyroid hormone receptor is mainly present. However, there is little knowledge concerning the prolonged effect of thyroid hormone deficiency throughout the rat's life span. We designed our study to investigate the role

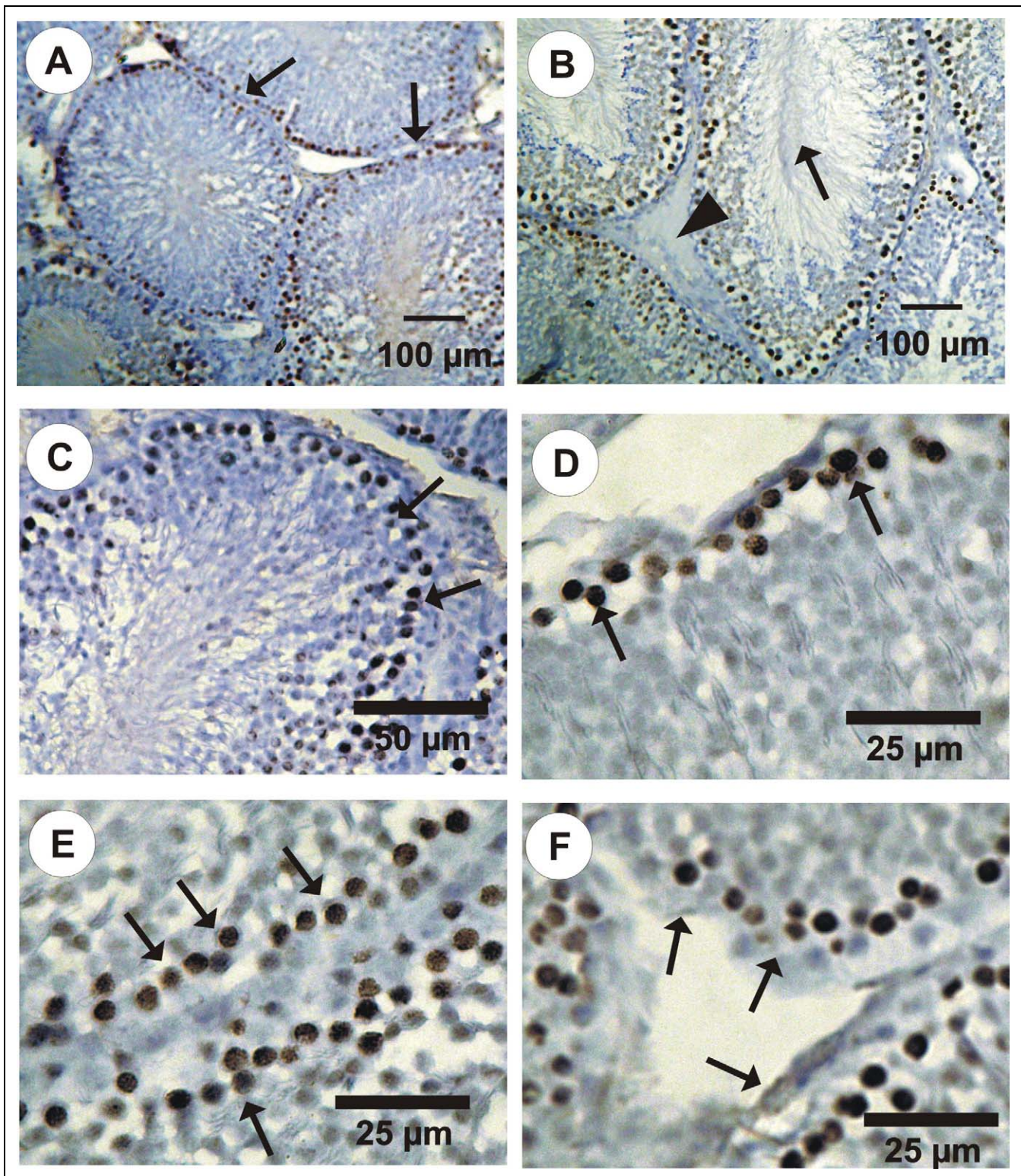


Figure 1. Photomicrographs of PCNA-ir (immunoperoxidase labelling) through in the testis cross-sections in control rats. A, Different stages of spermatogenic cells in the seminiferous tubules (arrows) showing the distribution of PCNA-ir positive cells in spermatogonia. B, The lumen of the seminiferous tubules is fully packed with sperm (arrows) and the negative reaction for PCNA-ir in Leydig cells (triangle). C-E, Positive reaction of PCNA-ir in spermatogonia (arrows). F, Negative reaction for PCNA-ir in Sertoli cells (arrows). PCNA indicates proliferating cell nuclear antigen.

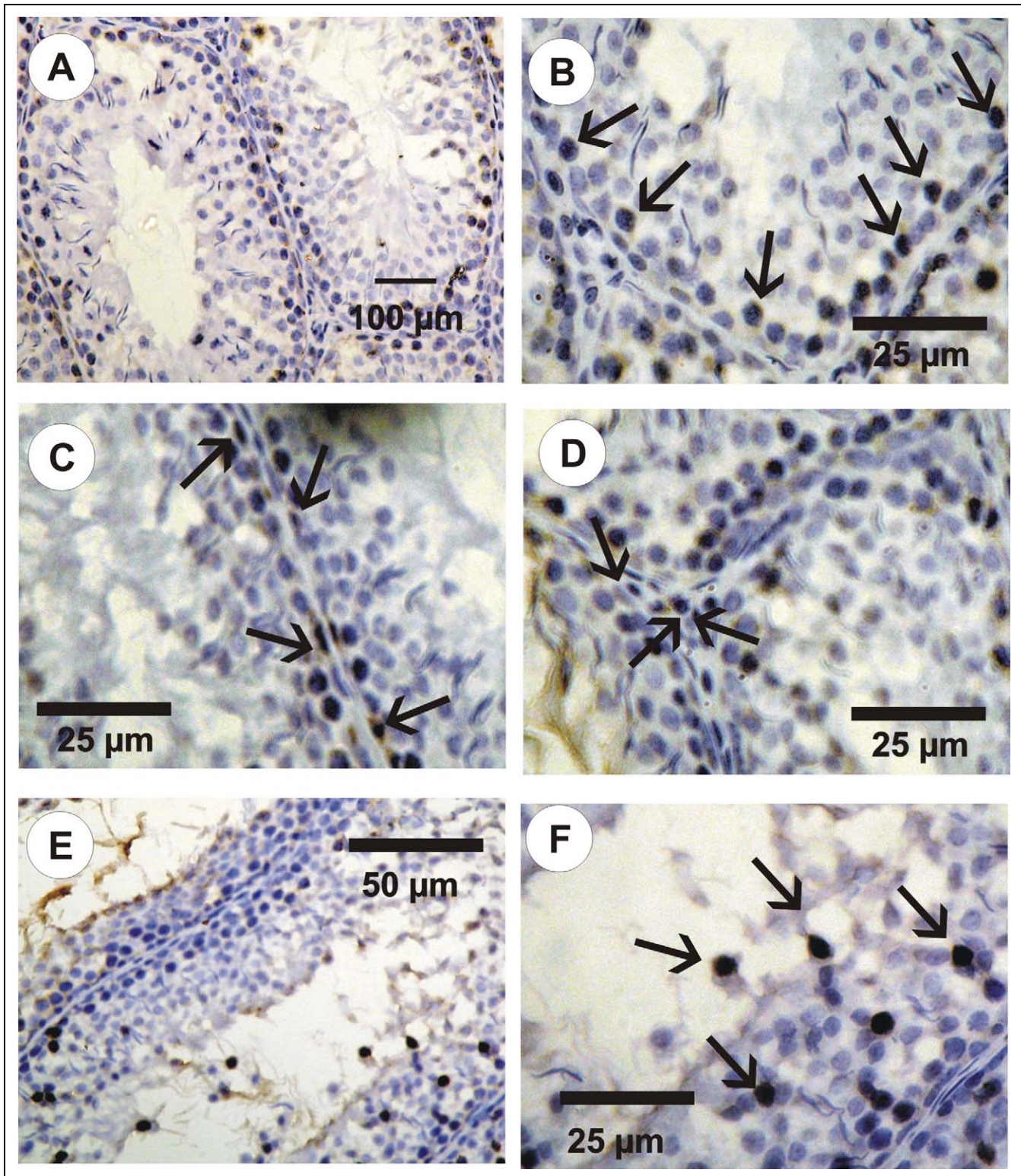


Figure 2. Photomicrographs of PCNA-ir (immunoperoxidase labelling) in the testes cross-sections in hypothyroid rats. A, Different stages of spermatogenic cells in the seminiferous tubules. Only a few numbers of spermatogonia have positive reaction for PCNA-ir. Note that the lumen of the tubules was clear and the spermatozoa were not seen. B, A few numbers of the spermatogonia in the seminiferous tubules have positive reaction for PCNA (arrows). C, A few numbers of the Sertoli cells (arrows) have a positive reaction for PCNA. D, A few numbers of the Leydig cells (arrows) have a positive reaction for PCNA. E and F, Abnormal distribution of spermatogonia (arrows) in seminiferous tubules of hypothyroid rats. PCNA indicates proliferating cell nuclear antigen.

of thyroid hormone on the testicular function at the prepubertal stage of rats. In order to achieve this target, we made a deficient state of thyroid hormones by a reversible goitrogen. 6-n-propyl thiouracil is known to decrease the conversion of peripheral T4 to T3 and thereby reduces serum T3 concentration. 6-n-propyl thiouracil has been linked with several side effects, such as transient leucopenia, jaundice, hepatomegaly, and vasculitis.³¹ It was administered to the rats in the drinking water within a period of 6 weeks to investigate the changes through a complete spermatogenic cycle.³²

In order to ensure the hypothyroid state, we regularly determined the serum T3 and TSH through the dose period, where serum T3 concentration is depressed and serum TSH concentration is significantly elevated. During normal spermatogenesis, controlled cell proliferation is of fundamental importance, assuming highly coordinated mechanisms between the mitotically inactive Sertoli cells and the germ cells undergoing mitosis and meiosis. Efficiency of spermatogenesis depends on the proliferative activity of spermatogonia and the loss of germ cells during meiosis and spermiogenesis.² Mitosis counts, tritiated thymidine ([³H]Thy) or 5-bromodeoxyuridine (BrdU) labeling have traditionally been used for the assessment of cell proliferation. However, these methods are less suitable for use under certain experimental conditions. For instance, [³H]Thy labeling requires use of radioisotopes, visualization by autoradiography, and *in vivo* administration, thus not enabling the use of this method in postmortem tissue.³³ With the development of monoclonal antibodies to DNA-incorporated BrdU,³⁴ the use of radioisotopes and autoradiographic visualization was eliminated. However, variability in BrdU concentration during the incubation period can affect the quality of labeling and thus influence the labeling index value.³³ Moreover, these methods require long fixation and development periods. Recently, the use of immunocytochemical assays, based on antibodies to cell proliferation-related antigens, has been shown to be effective in the assessment of cell proliferation.³⁵ One such cell proliferation-related protein³⁶ is PCNA that has been identified as an auxiliary protein of DNA polymerase δ ,³⁶ is found in the nuclei of proliferating cells. This antigen, which is differentially expressed during the cell cycle, reaches its maximum level of expression during late G1/S phase and begins to decrease during late G2/M to G1 phase.³⁷ Comparisons of PCNA- and BrdU-labeling indices have shown that not only does PCNA-labeling produce similar results to that of BrdU labeling, but it is a faster and easier method to use for the detection of cell proliferation.³⁸ In addition, because the PCNA method is based on an antigen-antibody reaction, it can be performed *in situ*, on routinely processed tissue sections. Quantitation of PCNA expression is becoming routinely used as a diagnostic tool in clinical pathology, for the assessment of tumor cell proliferation. However, we believe that because PCNA expression and synthesis is linked to cell proliferation,³⁵ and its presence subsequent to immunohistochemical processing can be observed microscopically, this technique may be

used for the purpose of providing direct visual evidence of cell proliferation under various experimental conditions.

The seminiferous epithelium contains 2 distinct cell populations, namely somatic Sertoli cells and spermatogenic cells. Spermatogonia undergo successive rounds of mitotic divisions and later the resulting daughter cells enter meiotic division to provide sperm. In the current study, we used immunohistochemistry to map the distribution of PCNA immunoreactivity in the testes of the control and hypothyroid rats. Proliferating cell nuclear antigen has been used extensively in the identification of proliferating spermatogonia and spermatocytes, which we observed as brownish black stained cells in our samples.

Our results indicate that hypothyroidism adversely affects spermatogenesis, suggesting that thyroid hormone might play an important role not only in controlling normal testicular development, but also in maintaining normal testicular function and spermatogenesis. These results indicate at least 4 differences in the pattern of PCNA immunoreactivity in the testes of hypothyroid rats in comparison to control ones. First, PCNA-ir were not detected in Sertoli cells in the testes of control rats and detected in hypothyroid rats. This finding confirmed the findings of Van Haaster et al,¹⁰ Tarulli et al,⁹ and Jansen et al⁸ regarding the role of thyroid hormone in regulating the maturation and growth of testis, in rats and other mammal species, by inhibiting immature Sertoli cell proliferation and stimulating their functional differentiation. Second, PCNA-ir were not detected in Leydig cells in the testes of control rats and were detected in hypothyroid rats confirming what mentioned by Mendis-Handagama and Ariyaratne¹¹ and Lin et al¹² regarding the critical role of thyroid hormones in the onset of Leydig cell differentiation and stimulation of steroidogenesis in postnatal rat testis. The third difference was in the number of spermatogonia that have a positive reaction for PCNA-ir in control and hypothyroid rats, all spermatogonia in control animals showed a positive reaction for PCNA-ir, while the number was smaller in hypothyroid rats as counted by PCNA-LI indicating a germinal arrest in the hypothyroid status (defected spermatogenesis). The fourth difference was in the abnormal distribution of spermatogonia seen in the hypothyroid rat testis in contrast to the control one, indicating a role of thyroid hormone in maintaining the normal distribution of the spermatogenic cells in the seminiferous tubules.

Declaration of Conflicting Interests

The authors declared no potential conflicts of interests with respect to the authorship and/or publication of this article.

Funding

The authors received no financial support for the research and/or authorship of this article.

References

1. Maran R, Ravichandran K, Arunakaran J, Aruldas MM. Impact of neonatal hypothyroidism on Leydig cell number, plasma, and

- testicular interstitial fluid sex steroids concentration. *Endocr Res*. 2001;27(1-2):119-141.
2. Toshihiro I. Thyroid hormone and atherosclerosis. *Vascul Pharmacol*. 2009;doi:10.1016/j.vph.2009.09.004.
 3. Bay K, Matthiesson KL, McLachlan RI, Andersson AM. The effects of gonadotropin suppression and selective replacement on insulin-like factor 3 secretion in normal adult men. *J Clin Endocrinol Metab*. 2006;91(3):1108-1111.
 4. Ge RS, Dong Q, Sottas CM, Papadopoulos V, Zirkin BR, Hardy MP. In search of rat stem Leydig cells: identification, isolation, and lineage-specific development. *Proc Natl Acad Sci USA*. 2006;103(8):2719-2724.
 5. Wagner SM, Wajner S, Maia A. The role of thyroid hormone in testicular development and function. *J Endocrinol*. 2008;199(3):351-365.
 6. Cooke PS, Holsberger DR, Witorsch RJ, et al. Thyroid hormone, glucocorticoids and prolactin at the nexus of physiology, reproduction, and toxicology. *Toxicol Appl Pharmacol*. 2004;194(3):309-335.
 7. Holsberger DR, Cooke PS. Understanding the role of thyroid hormone in Sertoli cell development: a mechanistic hypothesis. *Cell Tissue Res*. 2005;322(1):133-140.
 8. Jansen HT, Kirby J, Cooke PS, Arambepola N, Iwamoto G. Impact of neonatal hypothyroidism on reproduction in the male hamster, *Mesocricetus auratus*. *Physiology Behav*. 2007;90(5):771-781.
 9. Tarulli G, Stanton P, Lerchl A, Meachem S. Adult sertoli cells are not terminally differentiated in the Djungarian hamster: effect of FSH on proliferation and junction protein organization. *Biol Reprod*. 2006;74(5):798-806.
 10. Van Haaster LH, de Jong FH, Docter R, de Rooij DG. High neonatal triiodothyronine levels reduce the period of Sertoli cell proliferation and accelerate tubular lumen formation in the rat testis, and increase serum inhibin levels. *Endocrinology*. 1993;133(2):755-760.
 11. Mendis-Handagama SM, Siril Ariyaratne HB. Leydig cells, thyroid hormones and steroidogenesis. *Indian J Exp Biol*. 2005;43(11):939-962.
 12. Lin H, Hu G, Dong L, et al. Increased proliferation but decreased steroidogenic capacity in leydig cells from mice lacking cyclin-dependent kinase inhibitor 1B1. *Biology Reprod*. 2009;80(6):1232-1238.
 13. Gereben B, Zavacki AM, Ribich S, et al. Cellular and molecular basis of deiodinase-regulated thyroid hormone signaling. *Endocr Rev*. 2008;29(7):898-938.
 14. Faraone-Mennella MR, Ferone A, Marino L, et al. Poly (ADP-ribose)ylation of proteins and germ cell development in hyperthyroid rat testes. *Mol Cell Biochem*. 2008;323(1-2):119-129.
 15. Krassas GE, Papadopoulou F, Tziomalos K, Zeginiadou T, Pontikides N. Hypothyroidism has an adverse effect on human spermatogenesis: a prospective, controlled study. *Thyroid*. 2008;18(12):1255-1259.
 16. Krassas GE, Tziomalos K, Papadopoulou F, Pontikides N, Perros P. Erectile dysfunction in patients with hyper- and hypothyroidism: how common and should we treat? *J Clin Endocrinol Metab*. 2008;93(5):1815-1819.
 17. Wagner SM, Wajner S, Maia A. Is there a role for thyroid hormone on spermatogenesis? *Microsc Res Tech*. 2009;72(11):796-808.
 18. Madsen P, Celis JE. S-Phase patterns of cyclin (PCNA) antigen staining resemble topographical patterns of DNA synthesis. *FEBS Lett*. 1995;193(1):5-11.
 19. Waseem NH, Labib K, Nurse P, Lane DP. Isolation and analysis of the fission yeast gene encoding polymerase delta accessory protein PCNA. *EMBO J*. 1992;11(13):5111-5120.
 20. Zhang H, Xiong Y, Beach D. Proliferating cell nuclear antigen and p21 are components of multiple cell cycle kinase complexes. *Mol. Biol. Cell*. 1993;4(9):897-906.
 21. Hindges R, Hubscher U. DNA polymerase delta, an essential enzyme for DNA transactions. *Biol Chem*. 1997;378(5):345-362.
 22. Shivji MK, Kenny M, Wood RD. Proliferating cell nuclear antigen is required for DNA excision repair. *Cell*. 1992;69(2):367-374.
 23. Hall PA, Kearsley JM, Coates PJ, Norman DG, Warbrick E, Cox S. Characterisation of the interaction between PCNA and Gadd45. *Oncogene*. 1995;10:2427-2433.
 24. Waga S, Hannon GJ, Beach D, Stillman B. The p21 inhibitor for cyclin-dependent kinases controls DNA replication by interaction with PCNA. *Nature*. 1994;369(6481):574-578.
 25. Zeng L, Kong XT, Su JW, Xia TL, Na YQ, Guo YL. Evaluation of germ-cell kinetics in infertile patients with proliferating cell nuclear antigen proliferating index. *Asian J Androl*. 2001;3(1):63-66.
 26. Sahoo D, Roy A, Bhanja S, Chainy G. Hypothyroidism impairs antioxidant defence system and testicular physiology during development and maturation. General and comparative. *Endocrinology*. 2008;156(1):63-70.
 27. Latendresse JR, Warbritton AR, Jonassen H, Creasy DM. Fixation of testes and eyes using a modified Davidson's fluid: comparison with Bouin's fluid and conventional Davidson's fluid. *Toxicol Pathol*. 2002;30(4):524-533.
 28. Taghavi M, Moallem S, Alavi S. The evaluation of single dose effects of methamphetamine on proliferation and apoptosis of sperm germ cells in mature rat. *J Isfahan Med School*. 2009;27(97):100-109.
 29. Heller CH, Clermont Y. Kinetics of the germinal epithelium in man. *Recent Prog Horm Res*. 1964;20:545-575.
 30. Abdel-Dayem M. Histological and immunohistochemical changes in the adult rat testes after left experimental varicocele and possible protective effects of resveratrol. *Egypt J Histol*. 2009;32(1):81-90.
 31. Chiao YC, Cho WL, Wang PS. Inhibition of testosterone production by propylthiouracil in rat Leydig cells. *Biol Reprod*. 2002;67(2):416-422.
 32. de Kretser DM. Sertoli cell-Leydig cell interaction in the regulation of testicular function. *Int J Androl*. 1982;5(suppl 5):11-17.
 33. Linden MD, Torres FX, kubus J, Zarbo RJ. Clinical application of morphologic and immunocytochemical assessments of cell proliferation. *Am J Clin Pathol*. 1992;97(5 suppl 1):S4-S13.
 34. Gratzner HG. Monoclonal antibody to 5-bromo- and 5-iododeoxyuridine: a new reagent for detection of DNA replication. *Science*. 1982;218(4571):474-475.

35. Kurki P, Ogata K, Tan EM. Monoclonal antibodies to proliferating cell nuclear antigen (PCNA)/cyclin as probes for proliferating cells by immunofluorescence microscopy and flow cytometry. *J Immunol Meth.* 1988;109(1):49-59.
36. Bravo R, Frank R, Blundell PA, Macdonald-Bravo H. Cyclin/PCNA is the auxillary protein DNA polymerase delta. *Nature.* 1987;326(6112):515-517.
37. Celis JE, Celis A. Cell cycle dependent variations in the distribution of the nuclear protein cyclin/proliferating cell nuclear antigen in cultured cells: sub-division of S phase. *PNAS.* 1982;82(10):3262-3266.
38. Van Dierendonck JH, Wijsman JH, Keijzer R, van de Velde C, Corneliss C. Cell-cycle-related staining patterns of anti-proliferating cell nuclear antigen monoclonal antibodies. Comparison with BrdU labeling and Ki67 staining. *Am J Pathol.* 1991;138(5):1165-1172.