

BODIN, JEFFREY

ID:

11-Oct-2017 20:21:01

ST. Tammany Parish Hospital

20years
Male

Vent. rate 78 bpm
PR interval 142 ms
QRS duration 112 ms
QT/QTc 366/417 ms
P-R-T axes 83 85 82

Normal sinus rhythm
Right atrial enlargement
Borderline ECG

Room:
Loc: 3

Technician: BM
Test ind: MEDS

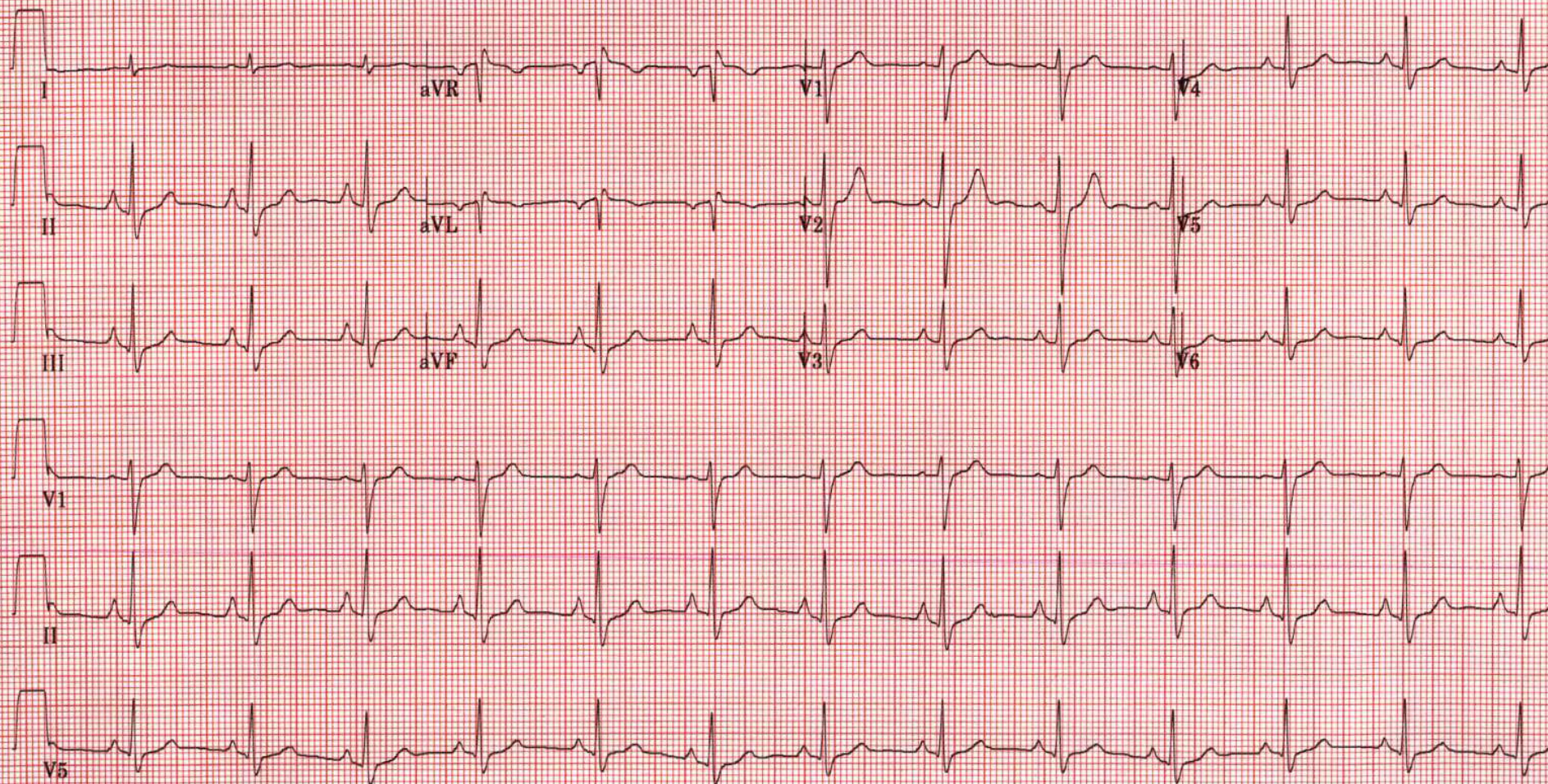
BODIN, JEFFREY
HAR: 11001253816 CSN: 92325565
DOB: 5/22/1997 (20 yrs) Male
MRN: 2592229
Adm Date: 10/11/2017



Referred by:

Unconfirmed

DOB: 5-22-97



40 Hz 25.0 mm/s 10.0 mm/mV

4 by 2.5s + 3 rhythm lds

MAC55 010A

12SL™ v241 HD