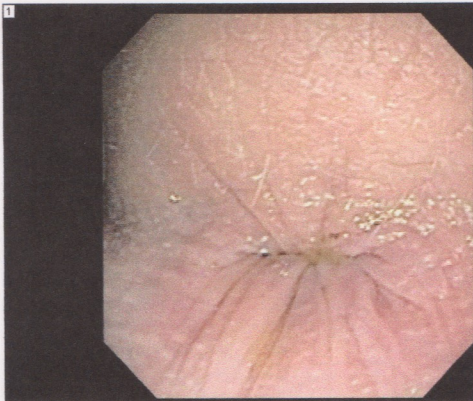


Children's Hospital of New Orleans

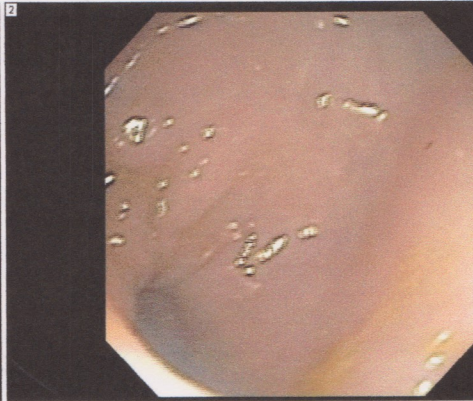
Colonoscopy Exam Images

Patient: Jeffrey Bodin
Patient ID: MRN-0445573
Exam Date: 10/15/2009

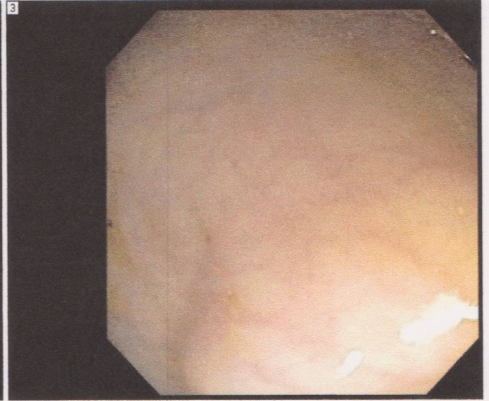
Attending Physician: Raynorda Brown M.D.
Referring Physician:



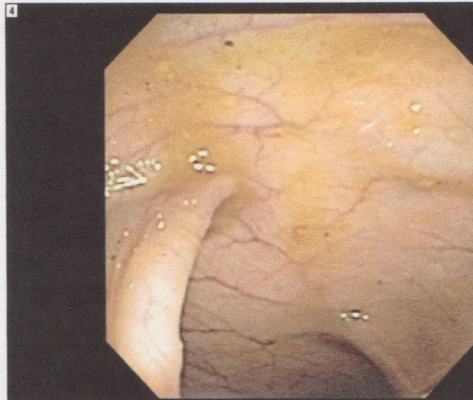
perianal area, normal



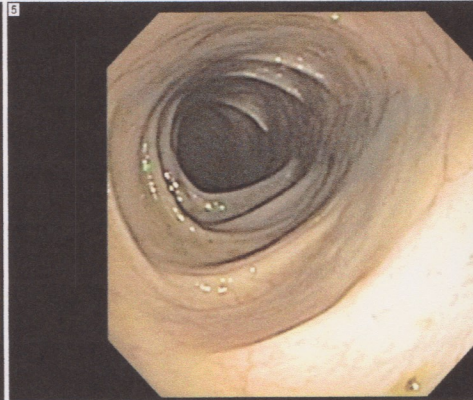
2]-Normal-anus



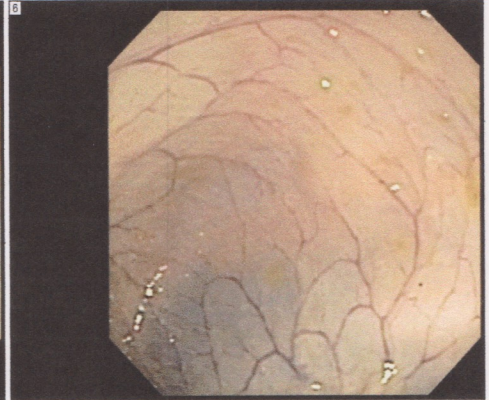
3]-Normal-rectum



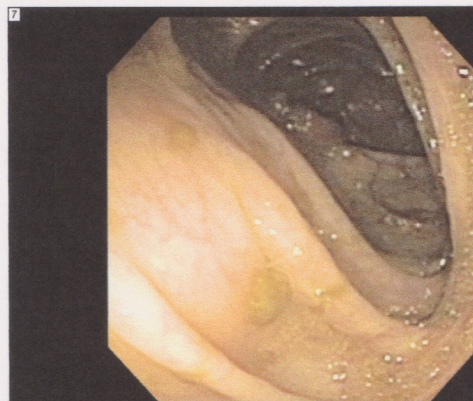4]-Normal-rectosigmoid junction



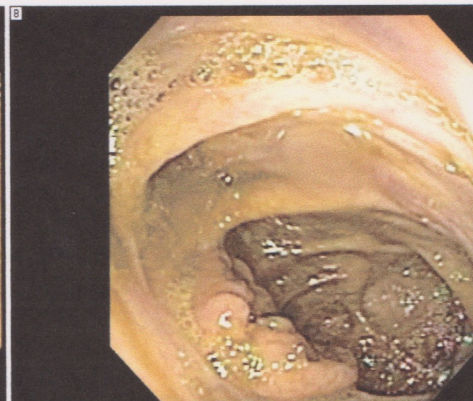
5]-Normal-descending colon



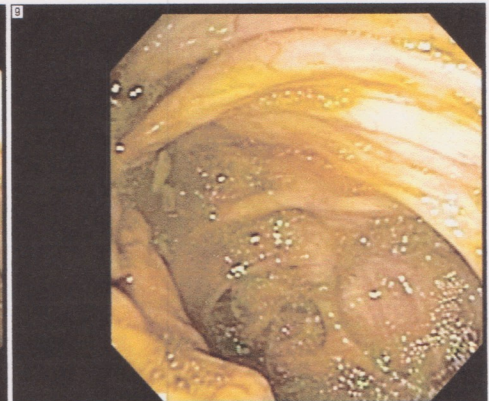
6]-Normal-hepatic flexure



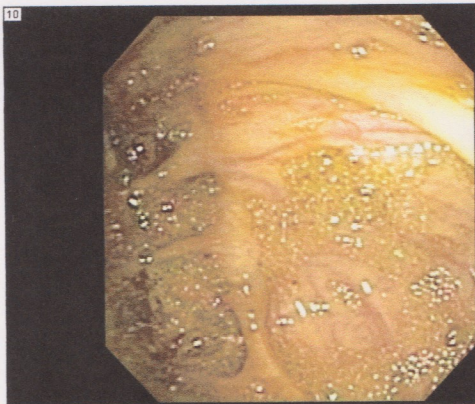
7]-Normal-proximal ascending colon



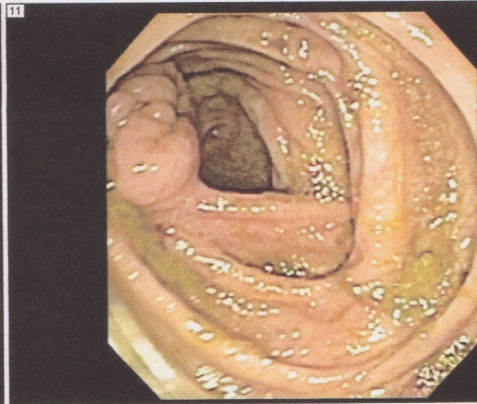
8]-Normal-ileocecal valve



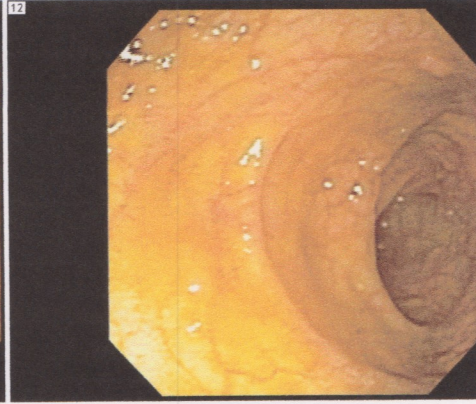
9]-Normal-cecum



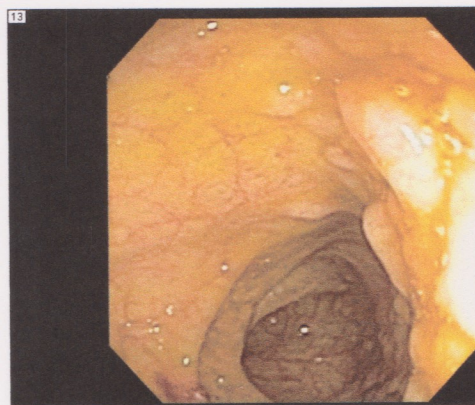10]-Normal-appendiceal orifice



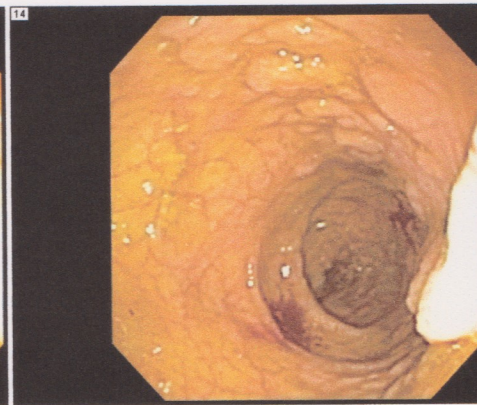
11]-Normal-ileocecal valve



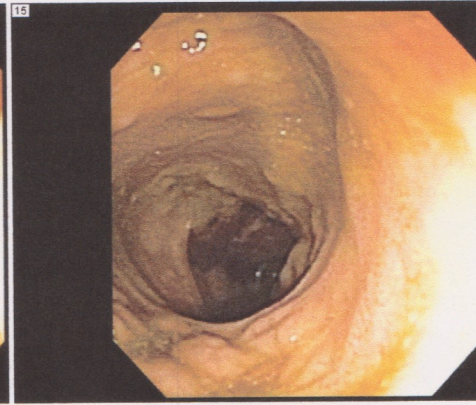
12]-Normal-terminal ileum



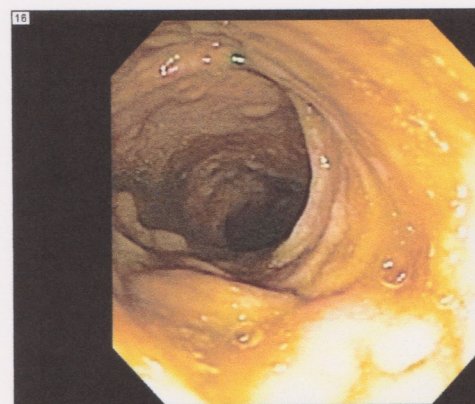13]-Normal-terminal ileum



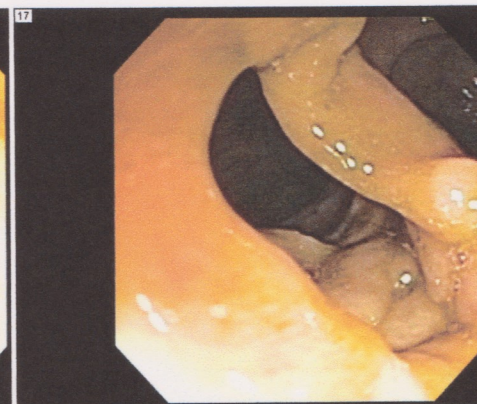
post biopsy, terminal ileum



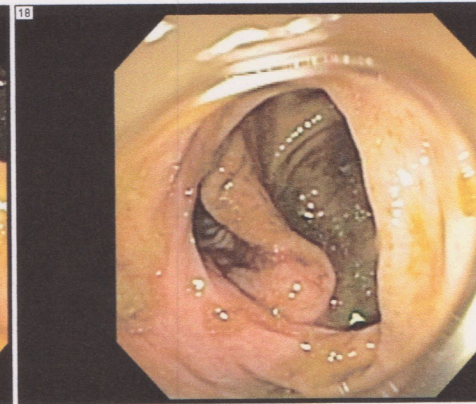
post biopsy, terminal ileum



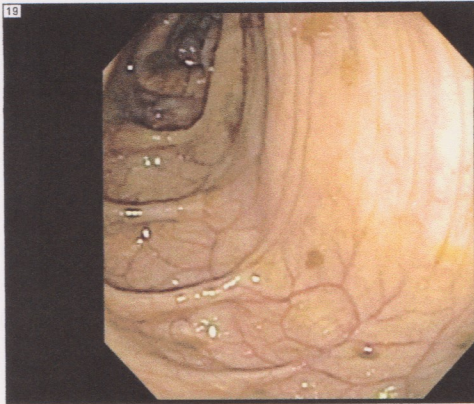
16]-Normal-terminal ileum



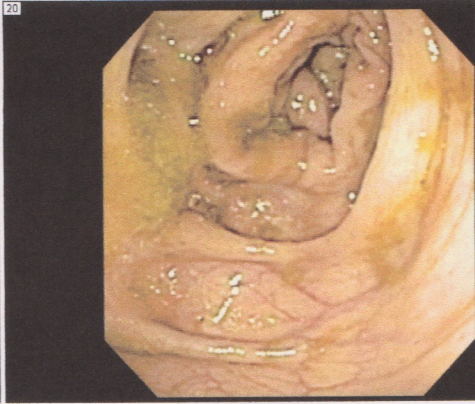
17]-Normal-ileocecal valve



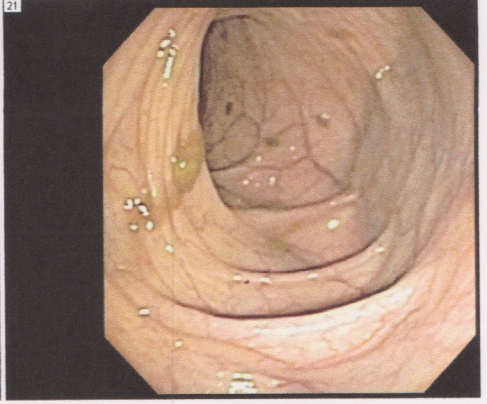
18]-Normal-ileocecal valve



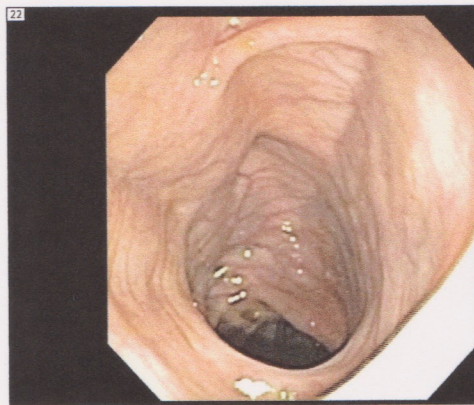
19-Normal-mid-ascending colon



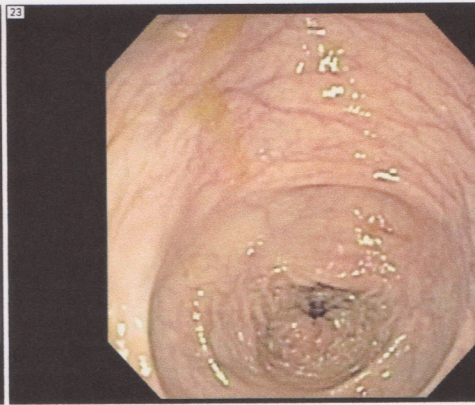
20-Normal-proximal ascending colon



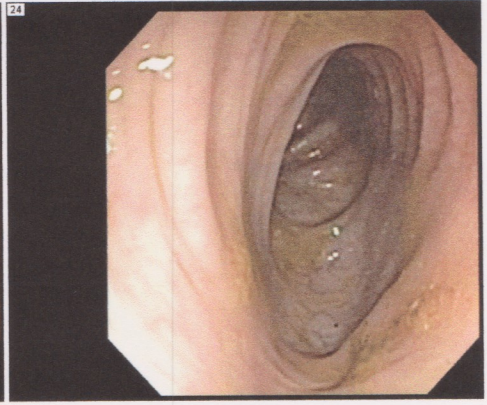
21-Normal-hepatic flexure



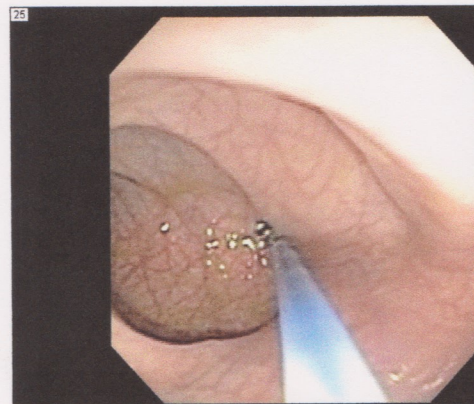
22-Normal-distal transverse colon



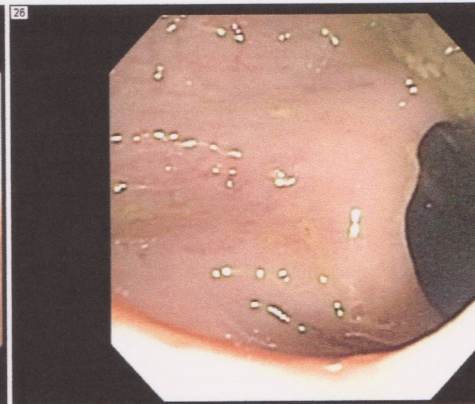
23-Normal-proximal descending colon



24-Normal-mid-sigmoid



25-Normal-rectum



26-erythematous mucosa-colon-rectum

MRN-0445573 Patient Name: Bodin, Jeffrey

